

# Arthrodesis of the tarsometatarsal joints in a cat with a two hole advanced locking plate system

R. Inauen; D. Koch; M. Bass

<sup>1</sup>Koch&Bass Referral Practice for Small Animal Surgery, Diessenhofen, Switzerland

## Summary

This report describes the successful use of the novel fixed-angle locking plating system ALPS (advanced locking plate system) in the case of dorsal tarsometatarsal instability in a cat. Partial arthrodesis of the tarsometatarsal joint was performed with a two hole ALPS 5 and two 2.4 mm selftapping locking screws through a small dorsal approach. Five days after the surgery the cat was walking without lameness. Radiographs made after six weeks showed uneventful healing. ALPS offers an alternative to existing plating systems when selecting an implant for the stabilisation of dorsal tarsometatarsal instabilities in cats.

## Keywords

ALPS, tarsometatarsal instability, cat, locking plate, titanium

Vet Comp Orthop Traumatol 2009; 22: 166–169

Prepublished online July 17, 2008  
doi:10.3415/VCOT-08-01-0007

## Introduction

Dorsal tarsometatarsal luxations in dogs or cats are sustained by traumatic incidents, such as falls from great height, the trapping of a limb, or road traffic accidents (1–3). The trauma mainly results in damage to the short dorsal ligaments, which span the joint spaces between the tarsal bones two to four and the metatarsal bones two to five (4). Movement between these bones is restricted to a minimum in physiologic conditions.

Depending on the degree of luxation or subluxation, different techniques of external or internal stabilisation have been described. External splinting is promoted (5) since there is minimal tension stress at the dorsal aspect of the tarsometatarsal region, providing sufficient stability to heal within four to six weeks without additional internal fixation. Temporary immobilisation with crossed pins, tension wiring or a plate are further treatment options (1, 5). However, early implant removal is recommended as soon as the periarticular fibrosis has stabilized the joints in order to avoid painful cartilage breakdown. Finally, partial arthrodesis involving the tarsometatarsal, and in some cases, the intertarsal joint rows as well, may be indicated. This is preferably done by plating, external fixation or cross pinning (2, 3, 5–9). This report describes the Advanced Locking Plate System (ALPS) and its use in a cat with dorsal tarsometatarsal instability.

The cross-section of the plate has a uniform moment of inertia along its entire length, known as the ‘Sharman-shape’ (Fig. 1). This plate profile enables more periosteal blood flow compared to standard plates, decreases the time to fracture healing, and increases the resistance to infections (10, 11, 12). The geometry of the


screw hole allows the insertion of either standard screws in different angulations, or larger locking screws in fixed 90° angulation to the plate (Fig. 2). The locking mechanism is accomplished by threads in the screw hole together with the last threads of the screw shaft. The screw is furthermore held in stable position by the conical shape (30°) of the screw head and the plate hole (Fig. 3). As the screw threads into the bone it pushes against the bottom of the plate threads causing the plate to lift slightly off the bone. As the last threads of the screw shaft have a reduced diameter underneath the screw head (Fig. 4), the plate is pulled back to the bone when the locking screw is fully engaged. The plate is produced from commercially pure titanium grade 4, and the screws from titanium alloy.

ALPS is currently available in sizes 5, 8 and 10, which can be used for similar indications as 2.0, 2.7 and 3.5 DCP, respectively (13). The screws are Torx® compatible (Fig. 4) manufactured as standard screws with a diameter of 1.5 mm, 2.4 mm and 2.7 mm, respectively, and locking screws with a diameter of 2.4 mm, 3.2 mm and 4.0 mm, respectively.

## Case history

A two-year-old spayed female domestic shorthair cat was presented with a non-weight bearing lameness of the left hind limb. Clinical examination, blood chemistry and haematology did not reveal any other abnormalities. Radiographs of the thorax did not show any signs of concurrent injuries. The tarsal region of the left hind limb was swollen. The cat showed a non-weight bearing lameness of the left hind limb. Latero-lateral and dorsoplantar radiographs of the tarsus revealed a dorsal separation of the

**Fig. 1**  
Shape of ALPS-plates.  
Lateral, dorsal and ventral view. The underside of ALPS makes only minimal contact with the bone preserving vascularity beneath the plate.



**Fig. 2**  
ALPS plate and screws. On the right and the left side are locked screws, the ones in the middle are conventional self tapping screws.



tarsometatarsal joints without further fragmentation (Figs. 5, 6). Whilst the cat was under general anaesthesia, the collateral and plantar ligaments were assessed as being intact, whereas dorsal stress produced joint instability. Further radiographs were not taken.

For exposure of the third tarsometatarsal joint space, a dorsal 3 cm skin incision was made and the extensor tendons and the

branches of the saphenous vein were gently retracted. The short ligaments were torn and the joints could be easily opened. The adjacent cartilage of the third tarsal bone and the third metatarsal bone were curetted with a sharp spoon, and osteostyxis was performed with a 1.5 mm drill.

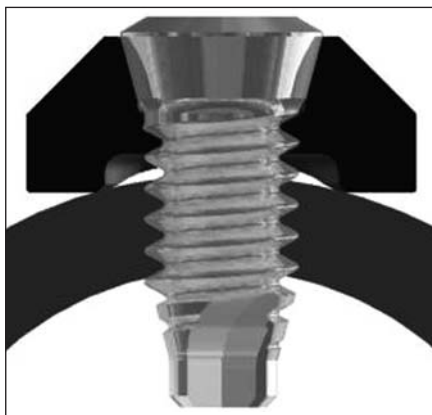
A two hole plate was cut off from a cuttable ALPS No.5 plate with 40 holes and held in place over the repositioned bones.

By using a special drill guide, allowing only 90° angulation to the plate, a 1.8 mm hole was drilled into the third tarsal bone. A 2.4 mm locking screw of 6 mm length was inserted and locked in the proximal plate hole. The procedure was repeated for the distal screw hole over the third metatarsal bone. The subcutaneous tissue and the skin were closed routinely. Mediolateral and plantarodorsal radiographs taken postoperatively confirmed anatomical reduction of the tarsometatarsal joint and accurate screw placement (Figs. 7, 8). A bandage was not applied.

The cat was sent home with analgetics on the same day. A period of 14 days of cage rest followed by three weeks of restricted activity was recommended to the owner. Five days after surgery the cat was without lameness and unrestricted activity was allowed as reported by the owner. By the time of the clinical examination after six weeks the cat was without lameness: The left tarsus was stable and without swelling and the control radiographs showed uneventful healing (Figs. 9, 10).

## Discussion

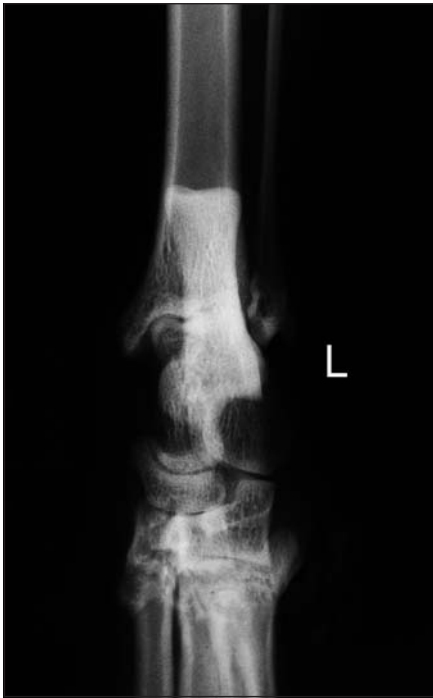Dorsal tarsometatarsal or intertarsal luxations in cats can be treated successfully with external coaptation (5), external fixators (8), tension band wiring (1), cross pins



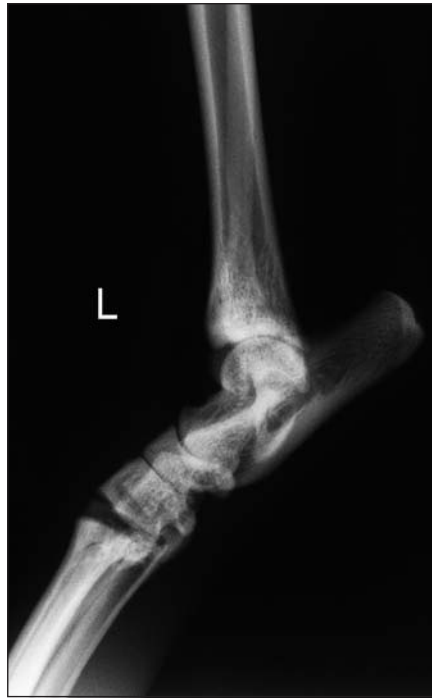**Fig. 3** Locked screw. The locking mechanism is accomplished by the thread in the plate and the first threads of the screw shaft. The screw is furthermore held in stable position by the conical shape of the screw head and the plate hole.

**Fig. 4**  
ALPS screws. On the left side is a view of the Torx®-compatible screw head. The 2.4 mm locking screw in the middle shows the cone shaped head, the special threads and the diameter of the screw. A conventional 1.5 mm self-tapping screw is on the right side.

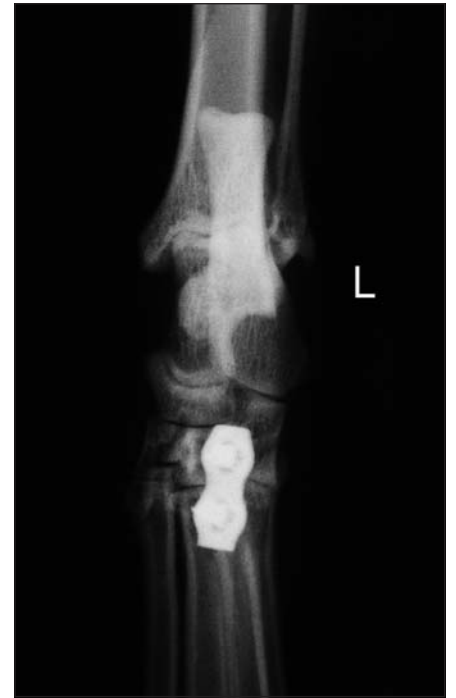



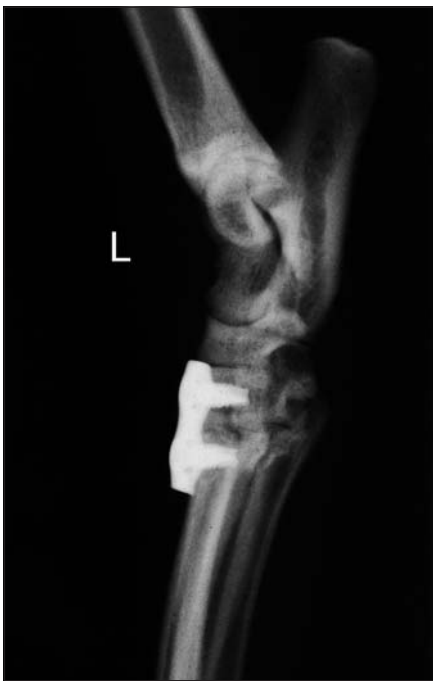**Fig. 5** Dorso-plantar view of the left tarsus, preoperative radiograph.



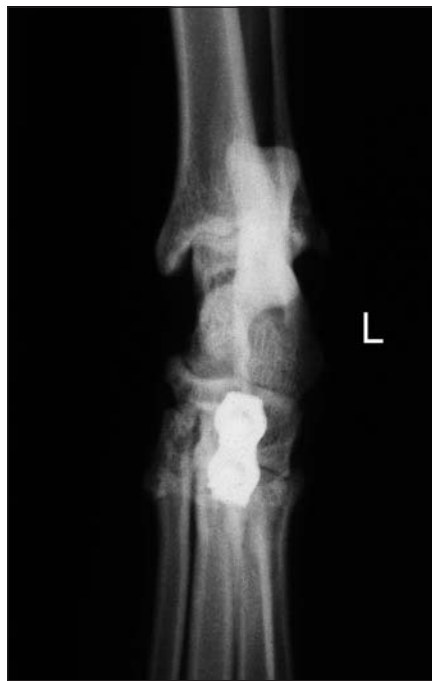**Fig. 6** Medio-lateral view of the left tarsus, preoperative radiograph.



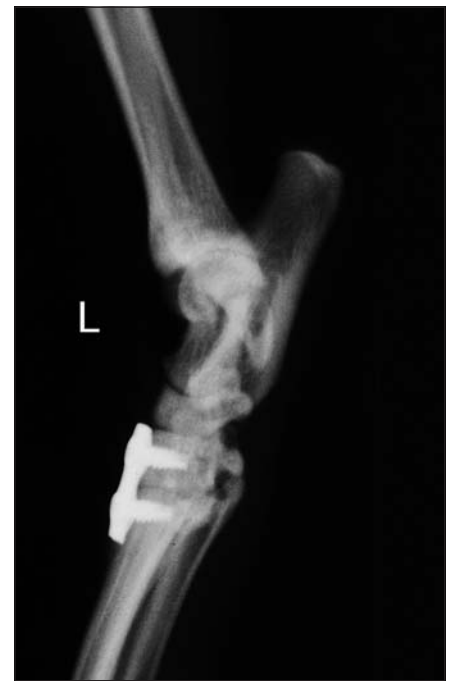**Fig. 7** Dorso-plantar view of the left tarsus, postoperative radiograph.



**Fig. 8** Medio-lateral view of the left tarsus, postoperative radiograph.



**Fig. 9** Dorso-plantar view of the left tarsus, radiograph six weeks postoperative.



**Fig. 10** Medio-lateral view of the left tarsus, radiograph six weeks postoperative.

(5), standard compression plates (2, 6, 7) or Uni-Lock systems (3). The ALPS system might be added to the list of fixation devices to treat this condition in cats as shown in this case report. Since none of the fixation methods have undergone biomechanical testing in the tarsal region of the cat or standardized follow-up to document clinical outcome, we focussed on the technical aspects of the ALPS and its main characteristics compared to other internal fixation techniques.

The main characteristic of ALPS is its locking mechanism between the screw and the plate. In the case of the 2.4 mm locking screw of the ALPS No.5 system, the main part of the screw is made with an outer diameter of 2.4 mm. Towards the screw head, where the screw shaft would finally lie between plate and bone, the diameter is reduced to 2.2 mm. This thread locks with the thread in the plate hole. The fixed-angle of the ALPS is further enhanced by the conical shape of the screw head. This locking mechanism differs from the UniLock and LCP systems, where threads in the conical screw head provide the locking effect (14). The PC-fix locking system relies on the intimate contact between the conical shape of the screw head and plate. The recently developed SOP® universal locking plate system provides angular stability by the thread in the plate hole fitting to the thread of a standard cortical bone screw.

The ALPS system combines the principles of the PC-Fix and the SOP with regard to angular stability, and preserves the blood supply to the bone underneath the plate (Fig. 1). The preservation of blood perfusion reduces the risk of infection and may lead to faster bone healing (10–12, 15).

Titanium and titanium alloys have been shown to reduce the rate of infections when

compared with stainless steel (16). Although not an issue in our case report, the overall risk for postoperative infections could be reduced by choosing an implant made from titanium.

A comparison between the ALPS 10 and the 3.5 broad DCP was made by finite analysis (Kyon, unpublished data), and this revealed that the strength of titanium ALPS 10 is higher than stainless steel 3.5 DCP.

In conclusion, the ALPS system is a useful device for fixation of dorsal tarsometatarsal luxation in cats and it might offer an alternative to other fixed-angle plate systems.

## References

- Guilliard MJ. Dorsal tarsal instability in three racing greyhounds. *J Small Anim Pract* 2003; 44: 415–417.
- Muir P, Norris JL. Tarsometatarsal subluxation in dogs: partial arthrodesis by plate fixation. *J Am Anim Hosp Assoc* 1999; 35: 155–162.
- Voss K, Keller M, Montavon PM. Internal splinting of dorsal intertarsal and tarsometatarsal instabilities in dogs and cats with the ComPact Uni-Lock 2.0/2.4TM System. *Vet Comp Orthop Traumatol* 2004; 17: 125–130.
- Evans H. Arthrology. In: Evans H, editor. *Miller's Anatomy of the Dog*. Philadelphia: W.B. Saunders 1993; 252–256.
- Piermattei D, Flo G. Fractures and other orthopedic injuries of the tarsus, metatarsus and phalanges. In: Piermattei D, Flo G, editors. *Handbook of Small Animal Orthopedics and Fracture Repair*. Philadelphia: W.B. Saunders Company 1997; 653–654.
- Dyce J, Whitelock RG, Robinson KV et al. Arthrodesis of the tarsometatarsal joint using a laterally applied plate in 10 dogs. *J Small Anim Pract* 1998; 39: 19–22.
- Fettig AA, McCarthy RJ, Kowaleski MP. Intertarsal and tarsometatarsal arthrodesis using 2.0/2.7-mm or 2.7/3.5-mm hybrid dynamic compression plates. *J Am Anim Hosp Assoc* 2002; 38: 364–369.
- McLennan MJ. Ankylosis of tarsometatarsal luxations using external fixation. *J Small Anim Pract* 2007; 48: 508–513.
- Rahal SC, Volpi RS, Hette K et al. Arthrodesis tarsocrural or tarsometatarsal in 2 dogs using circular external skeletal fixator. *Can Vet J* 2006; 47: 894–898.
- Eijer H, Hauke C, Arens S et al. PC-Fix and local infection resistance--influence of implant design on postoperative infection development, clinical and experimental results. *Injury* 2001; 32(Suppl 2): B38–43.
- Haas N, Hauke C, Schutz M et al. Treatment of diaphyseal fractures of the forearm using the Point Contact Fixator (PC-Fix): results of 387 fractures of a prospective multicentric study (PC-Fix II). *Injury* 2001; 32(Suppl 2): B51–62.
- Hertel R, Eijer H, Meisser A et al. Biomechanical and biological considerations relating to the clinical use of the Point Contact-Fixator--evaluation of the device handling test in the treatment of diaphyseal fractures of the radius and/or ulna. *Injury* 2001; 32(Suppl 2): B10–14.
- Miclau T, Remiger A, Tepic S et al. A mechanical comparison of the dynamic compression plate, limited contact-dynamic compression plate, and point contact fixator. *J Orthop Trauma* 1995; 9: 17–22.
- Keller MA, Voss K, Montavon PM. The ComPact UniLock 2.0/2.4 system and its clinical application in small animal orthopedics. *Vet Comp Orthop Traumatol* 2005; 18: 83–93.
- Fernandez Dell'Oca AA, Tepic S, Frigg R et al. Treating forearm fractures using an internal fixator: a prospective study. *Clin Orthop Relat Res* 2001; (389): 196–205.
- Arens S, Schlegel U, Printzen G et al. Influence of materials for fixation implants on local infection. An experimental study of steel versus titanium DCP in rabbits. *J Bone Joint Surg Br* 1996; 78: 647–651.

### Correspondence to:

Roman Inauen, DVM  
Koch&Bass Referral Practice for Small Animal Surgery  
Basadingerstrasse 26  
8253 Diessenhofen, Switzerland  
Phone: +41 52 657 47 57, Fax: +41 52 657 47 27  
E-mail: rinauen@kochbass.ch